

Moyamoya Disease

Overview

Moyamoya disease is caused by blocked arteries at the base of the brain. The name "moyamoya" means "puff of smoke" in Japanese and describes the appearance of tiny vessels that form to compensate for the blockage. As the normal blood vessels narrow and become blocked, a person may suffer a stroke. No medication can stop or reverse the progression of moyamoya disease. Treatment focuses on reducing the risk of stroke and restoring blood flow to the brain.

Blood supply of the brain

To understand moyamoya, it is helpful to understand the circulatory system of the head and neck (see Anatomy of the Brain). The carotid artery is the large artery whose pulse can be felt on both sides of the neck. It begins at the aorta as the common carotid artery and divides near the larynx into the external and internal carotid arteries. The external carotid arteries supply blood to the face and scalp. The internal carotid arteries supply blood to front and side areas of the brain.

Blood is carried to the brain by two paired arteries, the internal carotid arteries and the vertebral arteries (Fig. 1). The internal carotid arteries supply the anterior (front) areas and the vertebral arteries supply the posterior (back) areas of the brain. After passing through the skull, the right and left vertebral arteries join together to form a single basilar artery. The basilar artery and the internal carotid arteries "communicate" with each other in a ring at the base of the brain called the Circle of Willis.

Blood is carried to the face and scalp by the paired external carotid arteries. Behind the jaw the external carotid divides into the facial, maxillary, superficial temporal, and occipital arteries.

What is moyamoya disease?

Moyamoya disease is a chronic and progressive narrowing of the internal carotid arteries at the base of the brain where they divide into middle and anterior cerebral arteries. The walls of the arteries become thickened, which narrows the inside diameter of the vessel. The narrowing can eventually result in complete blockage and stroke. To compensate for the narrowing arteries, the brain

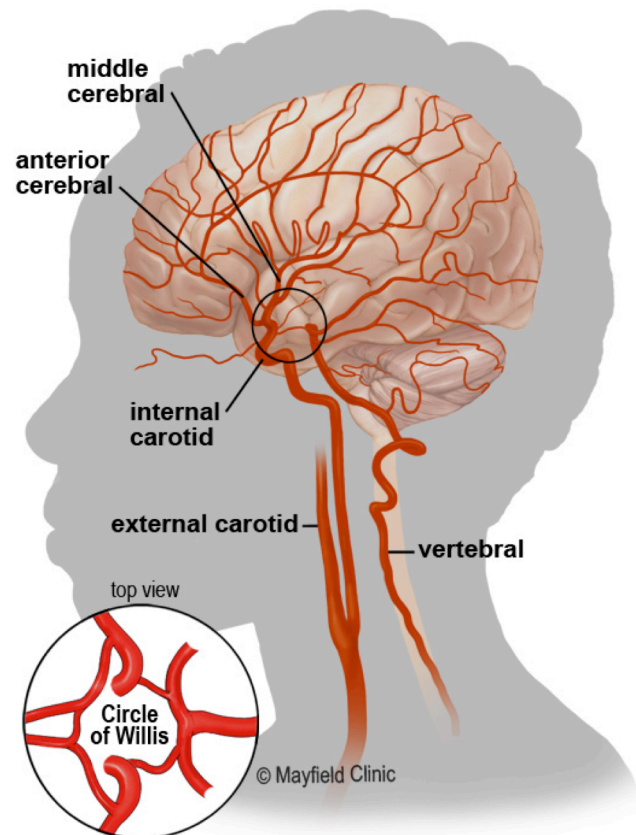


Figure 1. Side view and top view (lower left inset) of the brain's blood supply. The common carotid artery courses up the neck and divides into the internal and external carotid arteries. The brain's anterior circulation is fed by the internal carotid arteries (ICA) and the posterior circulation is fed by the vertebral arteries (VA). The two systems connect at the Circle of Willis by the anterior communicating and posterior communicating arteries.

creates collateral blood vessels in an attempt to deliver oxygen-rich blood to deprived areas of the brain. These tiny collateral vessels, when seen on an angiogram, have a hazy, filmy appearance. The Japanese were the first to describe the condition, and they named it "moyamoya," the Japanese term for "puff of smoke." More fragile than normal blood vessels, the tiny moyamoya collaterals can break and bleed into the brain, causing hemorrhages. Moyamoya usually affects both sides of the brain and is often accompanied by aneurysms.

The progression of Moyamoya follows a typical course and can be classified into stages based on angiography findings.

- Stage I: Narrowing of internal carotid arteries
- Stage II: Development of moyamoya vessels at the base of the brain
- Stage III: Intensification of moyamoya vessels and internal carotid artery narrowing (most cases diagnosed at this stage)
- Stage IV: Minimization of moyamoya vessels and increased collateral vessels from the scalp
- Stage V: Reduction of moyamoya vessels and significant internal carotid artery narrowing
- Stage VI: Disappearance of moyamoya vessels, complete blockage of internal carotid arteries, and significant collateral vessels from the scalp

Once the process of blockage (vascular occlusion) begins, it tends to continue. No known medication can reverse the blockage. Once a major stroke or bleeding has occurred, the patient may be left with permanent loss of function. It is important, therefore, to treat this condition promptly.

What are the symptoms?

Symptoms of moyamoya are most likely to first appear with an ischemic stroke, hemorrhagic stroke, or mini-stroke, also known as a transient ischemic attack (TIA). During an ischemic stroke or TIA, a blockage interrupts the flow of oxygen-carrying blood to the brain. Hemorrhagic stroke results when tiny blood vessels burst and leak blood into the brain. Both ischemic and hemorrhagic stroke symptoms can include weakness or numbness in an arm or leg, difficulty speaking, or paralysis affecting one side of the body. Other symptoms include seizures and cognitive or learning impairments. Headache is also common in hemorrhagic stroke.

What are the causes?

The exact cause of moyamoya disease is unknown. Inheritance (family history) may play a role, especially in people of Japanese origin (10%).

Several diseases are associated with moyamoya-like changes. Although not common, Moyamoya syndrome can occur in patients with neurofibromatosis type I, sickle cell disease, and Down's syndrome. Moyamoya-like changes can also occur in patients who have undergone radiation or radiotherapy to the head and neck such as in treatment of pituitary tumors and craniopharyngiomas.

Who is affected?

Although moyamoya disease is most prevalent in Japan, it has been diagnosed in people throughout the world. In the United States, the risk of developing moyamoya is less than one in 100,000. It can occur at any time, but is most commonly diagnosed in children aged 5 to 15 and in adults aged 30 to 40.

How is a diagnosis made?

If you are experiencing stroke-like symptoms, you may be referred to a neurosurgeon. The surgeon will learn as much as possible about your symptoms, current and previous medical problems, current medications, and family history. He or she also will perform a physical exam. Diagnostic imaging tests are performed to detect the characteristic arterial narrowing and collateral blood vessels of moyamoya that have the appearance of a "puff of smoke." Imaging also can reveal evidence of multiple small strokes. Doctors can usually make a diagnosis of moyamoya if MRI images show 1) diminished blood flow in the internal carotid artery and the middle and anterior cerebral arteries and 2) prominent collateral blood flow at the base of the brain. To confirm the diagnosis of moyamoya disease, an angiogram is typically required.

- **Magnetic Resonance Imaging (MRI)** scan is a noninvasive test that uses a magnetic field and radio-frequency waves to give a detailed view of the soft tissues of your brain. An MRA (Magnetic Resonance Angiogram) is performed during an MRI by injecting a contrast agent into the blood stream so that arteries of the brain can be seen (Fig. 2). The doctor may first order

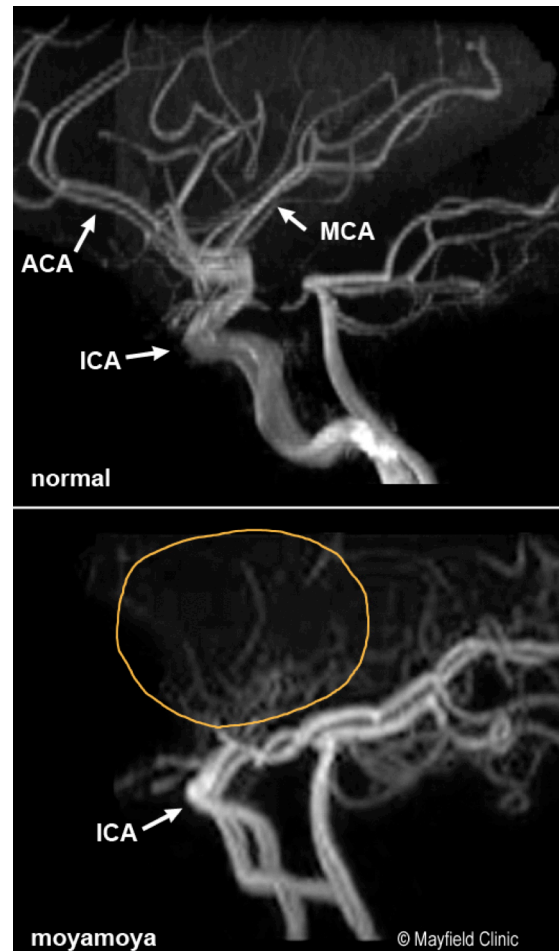


Figure 2. (side view) MRA scans of the normal cerebral blood vessels (above) and of Moyamoya (below) showing absence of the anterior cerebral artery and a profuse collateral network of basal vessels (circled area).

an MRI of the brain to determine if you have had any strokes recently or in the past.

- **Angiogram** is an invasive procedure in which a catheter is inserted into an artery and passed through the blood vessels to the brain. Once the catheter is in place, a contrast dye is injected into the bloodstream and X-ray images are taken. This test examines all the major arteries to the brain, including the external carotid arteries, internal carotid arteries, and vertebral arteries. Imaging is essential to identify pre-existing collateral vessels, so that surgery, if performed, will not disrupt them (Fig. 3). Aneurysms or arteriovenous malformations (AVMs), known to be associated with moyamoya, can also be detected.
- **Computed Tomography Angiography (CTA)** scan is a noninvasive X-ray that provides detailed images of anatomical structures within the brain. It involves injecting a contrast agent into the blood stream so that arteries of the brain can be seen. This type of test provides the best pictures of both blood vessels (through angiography) and soft tissues (through CT).
- **Computed Tomography (CT) Perfusion** imaging is a noninvasive test that detects blood flow in the brain and is used in planning surgery. It involves injecting a contrast agent into the blood stream so that doctors 1) can study how much blood flow is reaching the brain and 2) can determine which areas of the brain are most at risk of stroke. During the test a medication called Diamox (acetazolamide) is given to dilate the arteries. This medication is a type of "stress test" for the brain and is similar to a stress test used for the heart.
- **Cerebral blood flow studies**, such as transcranial Doppler ultrasonography (TCD), xenon-enhanced CT, positron emission tomography (PET), and single photon emission computed tomography (SPECT), also can help physicians with their diagnosis and treatment of patients with moyamoya.

What treatments are available?

There are no medications capable of reversing the artery narrowing in moyamoya disease. Instead, treatment focuses on reducing the risks of repeated strokes through arterial bypass or the creation of a new blood supply to the affected areas of the brain.

Medications

For those experiencing strokes and TIAs, medications such as aspirin may reduce the risk of a damaging stroke. Research has shown that aspirin alone is ineffective in treating moyamoya.

Surgical treatments

Surgery is generally recommended for moyamoya patients with recurrent or progressive TIAs or strokes. Several different surgeries are available, all with the goal of preventing further strokes by

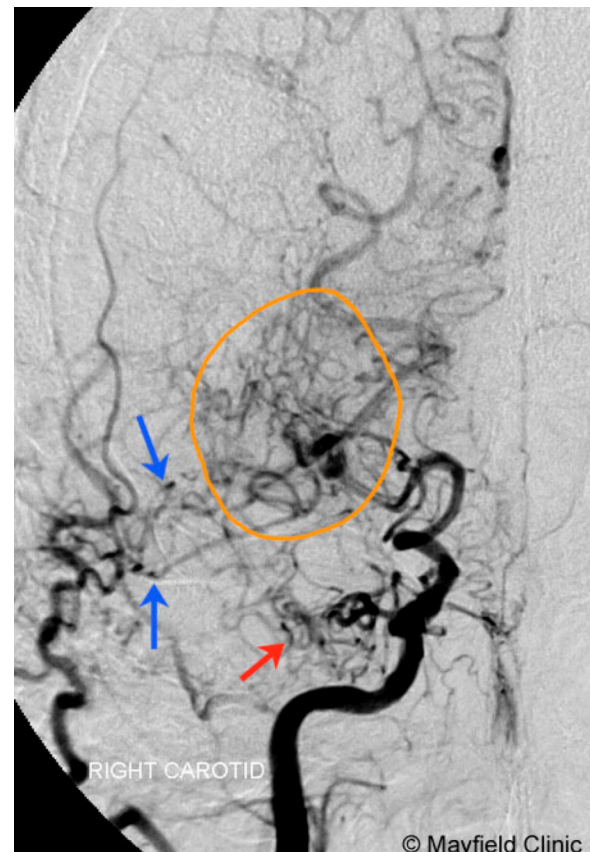


Figure 3. (front view) Angiogram of the right carotid artery showing occlusion of the intracranial carotid bifurcation with collateral blood flow originating from the external carotid artery (blue arrows), and basal arteries (red arrow), creating the characteristic "puff of smoke" (circled area).

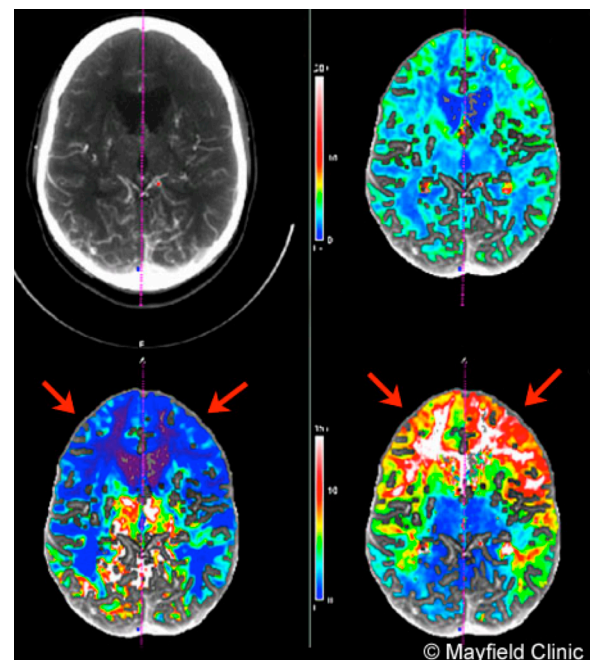


Figure 4. CT perfusion scans show areas of the brain that have decreased blood flow (red arrows) caused by moyamoya disease.

restoring (revascularizing) blood flow to the affected areas of the brain. The procedures, which can be divided into two groups, involve direct or indirect connection between the blood vessels. In general, direct bypass procedures are performed in adults and older children, while indirect procedures are preferred for children under the age of 10.

- **Cerebral bypass procedure** is a direct method of revascularization. It involves connecting a blood vessel from outside the brain to a vessel inside the brain to reroute blood flow around an artery that is narrowed, blocked, or damaged. The most common bypass procedure, the STA-MCA (superficial temporal artery to middle cerebral artery), may achieve instant improvement in blood flow (Fig. 5). Occasionally, if the superficial temporal artery is not available or not big enough to use in the bypass, then another artery must be utilized. This will be determined when your surgeon reviews the images of your arteries from your angiogram or CT angiogram.
- **EDAS (encephalo-duro-arterio-synangiosis) procedure** is an indirect method of revascularization in which the superficial temporal artery is placed in contact with the brain surface. A hole is cut in the skull directly beneath the artery. The artery is then sutured to the surface of the brain and the bone replaced. Over time, angiogenesis results in the formation of small arterial vessels to the brain. The integrity of the STA is maintained; the vessel is not harvested, as in the direct bypass technique.
- **EMS (encephalo-myo-synangiosis) procedure** is an indirect method of revascularization in which the temporalis muscle on the side of the head, is dissected and, through an opening in the skull, is placed onto the surface of the brain. Over time, new vessels form between the blood-rich muscle and the brain.
- **EDAMS (encephalo-duro-arterio-myo-synangiosis) procedure** is an indirect method of revascularization. It combines the technique of EDAS and EMS.
- **Omental transposition procedure** is an indirect method of revascularization in which the omentum (the lining surrounding the abdominal organs), which is very rich in blood supply, is placed on the surface of the brain, with the expectation that vessels will eventually grow into the brain and improve blood supply.
- **Multiple burr holes procedure** is an indirect method of revascularization in which several small holes (burr holes) are placed in the skull to allow for growth of new vessels into the brain from the scalp.

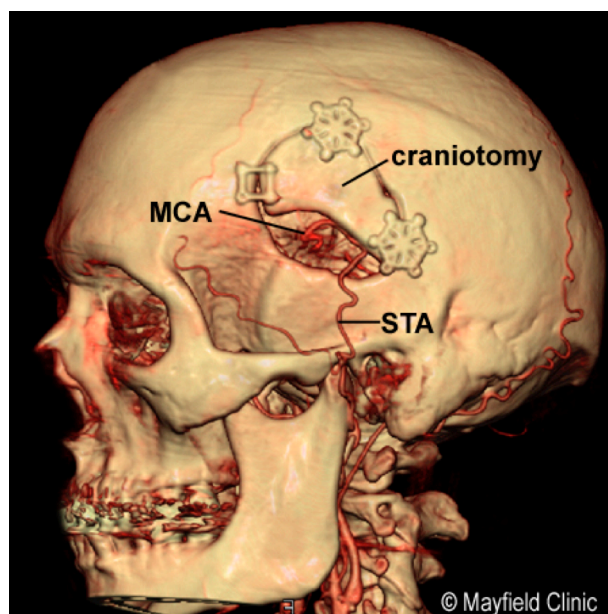


Figure 5. The superficial temporal artery (STA) is routed through a hole in the skull, called a craniotomy, and is connected to the middle cerebral artery (MCA) to restore blood flow to the brain.

Clinical trials

Clinical trials are research studies in which new treatments—drugs, diagnostics, procedures, and other therapies—are tested in people to see if they are safe and effective. Research is always being conducted to improve the standard of medical care. Information about current clinical trials, including eligibility, protocol, and locations, are found on the Web. Studies can be sponsored by the National Institutes of Health (see clinicaltrials.gov) as well as private industry and pharmaceutical companies (see www.centerwatch.com).

Recovery

The prognosis for patients with moyamoya is difficult to predict because the disease's natural history is not well known. Moyamoya can progress slowly with occasional TIAs or strokes, or it can involve rapid decline. The overall prognosis for patients with moyamoya disease depends on how rapidly vascular blockage occurs, and to what extent. Prognosis also is determined by the patient's ability to develop effective collateral circulation, the age at onset of symptoms, and the severity of disability resulting from a stroke. The patient's neurologic condition at the time of treatment is more important in determining long-term outcome than the patient's age.

Scientists have estimated that among untreated patients with moyamoya, 50 to 66 percent will experience progression of the disease and will suffer poor outcomes. By contrast, a large analysis of surgically treated pediatric patients found disease progression in an estimated 2.6 percent of patients. A more recent review of untreated patients who had no symptoms found an annual stroke rate of 3.2 percent and disease progression in 80 percent. [4,5]

If a patient is surgically treated prior to a disabling stroke, even if the condition is severe, the prognosis tends to be excellent. Even in patients without symptoms, surgical treatment has been reported to protect against stroke. However, if left untreated, the disease will invariably progress, producing clinical deterioration and potentially irreversible neurological deficits over time. For patients who have long-term damage from strokes, treatment will also focus on physical therapy, speech therapy, and occupational therapy to help them regain function and cope with any remaining disability.

Sources & links

If you have more questions, please contact Mayfield Brain & Spine at 800-325-7787 or 513-221-1100.

Sources

1. Burke GM, Burke AM, Sherma AK, Hurley MC, Batjer HH, Bendok BR. Moyamoya disease: a summary. *Neurosurg Focus* 26(4):E11, 2009
2. Baaj AA, Agazzi S, Sayed ZA, Toledo M, Spetzler RF, van Loveren H. Surgical management of moyamoya disease: a review. *Neurosurg Focus* 26(4):E7, 2009
3. Scott, R.M. and Smith, E.R. Moyamoya Disease and Moyamoya Syndrome. *New England Journal of Medicine* 360:1226-37, 2009
4. Guzman R, Lee M, Achrol A, et al. Clinical outcome after 450 revascularization procedures for moyamoya disease. *J Neurosurg* May 22, 2009
5. Kuroda S, Houkin K. Moyamoya disease: current concepts and future perspectives. *Lancet Neurol* 7:1056-1066, 2008.

Links

www.moyamoya.com

Glossary

anastomosis: the connection of normally separate parts or spaces so they intercommunicate, as between two blood vessels.

angiogenesis: the process of developing new blood vessels.

cerebral bypass: an operation in which a surgeon creates a new pathway for the movement of fluids and/or other substances in the brain.

collateral vessels: a branch of an artery or vein used as an accessory to the blood vessel from which it arises; often develop to shunt blood around a blockage.

ischemic stroke: stroke caused by an interruption or blockage of oxygen-rich blood flow to an area of the brain; caused by a blood clot, atherosclerosis, vasospasm or reduced blood pressure.

hemorrhagic stroke: stroke caused by the rupture of a blood vessel in the brain.

Moyamoya disease: a narrowing of the internal carotid arteries at the base of the brain that can eventually result in complete blockage and stroke. To compensate for the narrowing arteries, the brain creates collateral blood vessels in an attempt to deliver oxygen-rich blood to deprived areas of the brain.

Moyamoya syndrome: a condition with moyamoya-like changes to the internal carotid arteries but caused by a known disease.

occlusion: an obstruction or closure of a passageway or vessel.

revascularization: to restore blood supply to an organ by means of a blood vessel graft.

transient ischemic attack (TIA): a "mini" stroke caused when blood flow to the brain is temporarily interrupted and then restored; causes no permanent brain damage.



updated > 4.2018

reviewed by > Andrew Ringer, MD, Mayfield Clinic, Cincinnati, Ohio

Mayfield Certified Health Info materials are written and developed by the Mayfield Clinic. We comply with the HONcode standard for trustworthy health information. This information is not intended to replace the medical advice of your health care provider. © Mayfield Clinic 1998-2018.